

# Propofol-induced postoperative unconsciousness in hepatocellular carcinoma

Mohammad Faiz Taqiyuddin **Mohd Nor**, Nurul 'Aifaa **Mohd Azmi**, Wan Fadzlina **Wan Muhd Shukeri**, Shamsul Kamalrujan **Hasan**

*Department of Anaesthesiology and Critical Care, Universiti Sains Malaysia, Kubang Kerian, Kelantan, Malaysia*

## Abstract

Although propofol is a commonly used medication for inducing general anaesthesia, it is not without side effects. In this case report, we present a patient with hepatocellular carcinoma who experienced postoperative unconsciousness following general anaesthesia induction using propofol. While this is a rare occurrence, it underscores the importance of remaining vigilant and understanding propofol's pharmacokinetic properties. The drug can be redistributed from fat tissues into the systemic circulation, resulting in delayed recovery and potential adverse effects. We also discuss the possible impact of disease interactions, particularly hepatic impairment with possible CYP450 deficiency, on propofol metabolism. We stress the necessity of closely monitoring patients during anaesthesia induction and maintenance.

*Keywords:* CYP450 deficiency, postoperative unconsciousness, propofol

---

**Correspondence:** Mohammad Faiz Taqiyuddin Bin Mohd Nor, Department of Anaesthesiology and Intensive Care, School of Medical Sciences, Universiti Sains Malaysia, Jalan Raja Perempuan Zainab 2, 16150, Kubang Kerian, Kelantan, Malaysia.  
E-mail: faiztaqiu@usm.my

---

## Introduction

Postoperative unconsciousness with propofol induction is a rare incident that occurs in 1/10,000 cases.<sup>1</sup> Recovery from anaesthesia with the use of propofol is usually rapid. However, in our case, the redistribution of propofol from fat tissues into the systemic circulation after propofol induction and maintenance of anaesthesia caused our patient to experience a loss of consciousness post-extubation. Here, we will discuss propofol and its side effects, as well as disease interactions with propofol that may interfere with drug metabolism and pharmacokinetics.

## Case presentation

A 37-year-old Malay female, weighing 55 kg, with a known case of hepatocellular carcinoma (HCC) presented to our centre on 25 October 2022 for a scheduled computerised tomography (CT)-guided microwave coagulation therapy (MCT) of HCC under general anaesthesia. The patient had previously been diagnosed with hepatitis B in April 2022 but was otherwise healthy, with all blood test results being normal and classified as Child Pugh A. Her blood results are shown in Table 1.

Table 1. Results of admission investigations

Haematology		Biochemistry		Liver function test	
Hb	11.4 g/dL	Urea	1.8 (mmol/L)	ALB	31 g/L
WBC	5.72 (x 10 <sup>9</sup> /L)	Sodium	138 (mmol/L)	ALP	166 U/L
Platelets	299 (x 10 <sup>9</sup> /L)	Potassium	3.8 (mmol/L)	ALT	15 U/L
PT	15.6 secs	Chloride	109 (mmol/L)	AST	70 U/L
INR	1.16	Creatinine	54 (µmol/L)	Bilirubin	23 µmol/L
APTT	42 secs				

ALB: albumin; ALP: alkaline phosphatase; APTT: activated partial thromboplastin time; AST: aspartate aminotransferase; ALT: alanine transaminase; Hb: haemoglobin; INR: international normalized ratio; PT: prothrombin time

On the day of the event, she was electively intubated at the operating theatre and induced with intravenous (IV) fentanyl 100 mcg, IV propofol 150 mg, and IV rocuronium 50 mg. She was then transported with IV injection (IVI) of fentanyl and propofol to the radiology department for the procedure.

Upon arrival, however, there was a technical error with the ventilator machine; hence, we were unable to maintain anaesthesia using sevoflurane gas. As the patient's sedation weaned off after transitioning from IV sedation to gas sedation, the patient required multiple boluses of IV propofol to deepen the sedative effect. For the first hour of the procedure, anaesthesia was maintained with IVI propofol 1% (5–20 ml/h) (as no target-controlled infusion pump was available) and IVI fentanyl (10 mcg/ml) run at 2–4 ml/h.

The ventilator issue was resolved after a while, and we were able to switch back to sevoflurane to maintain anaesthesia. The intraoperative period was uneventful, with stable haemodynamic parameters and no desaturation episodes observed throughout the procedure. The patient successfully underwent MCT of liver lesions in segments II/III and VI. Intraoperative analgesia included IV paracetamol (1 g), IV magnesium sulfate (2.47 g), and IV morphine (6 mg). She was then transported back to the operating theatre for extubation and reversed with IV sugammadex 200 mg. Her Aldrete and Post Anaesthetic Discharge Scoring System scores post-extubation were 8 and 6, respectively, and she was sent to the ward after 30 minutes of monitoring in the recovery bay area.

However, upon arrival at the ward, the patient was unresponsive to calls and reported having laboured breathing. Glasgow Coma Scale (GCS) documented E1V1M1, but hemodynamically stable, with no desaturation episode and normal serum glucose (10.6 mmol/L). She was then transferred to the intensive care unit (ICU) and re-intubated for poor GCS. She received intermittent positive pressure ventilation overnight, and her GCS improved to E4VTM6 the next day, allowing her to be successfully extubated. As no significant causes for her unconsciousness were identified, we postulated that her GCS drop might have been due to remnants of the propofol effect, unmetabolised due to liver impairment. This was further evidenced by her liver enzymes rising from baseline upon ICU admission (Table 2).

The patient was also scheduled for a CT scan of the brain to rule out any potential pathology that may have contributed to the event, but she died due to advanced HCC with lung metastasis in January 2023.

Table 2. Serial liver function test investigation

Variable	25/10/22	26/10/22 (post MCT)	27/10/22 (2 <sup>nd</sup> day ICU)	9/11/22 (Clinic follow-up)	Normal range
AST (U/L)	70	152	195	76	5–34
ALT (U/L)	15	34	47	15	< 34
ALP (U/L)	166	144	134	165	42–98
ALB (g/L)	31	28	28	31	38–44
Total protein (g/L)	69	62	62	70	

ALB: albumin; ALP: alkaline phosphatase; AST: aspartate aminotransferase; ALT: alanine transaminase; MCT: microwave coagulation therapy

## Discussion

Propofol, chemically described as 2,6-diisopropylphenol, is a commonly used IV anaesthetic agent that can produce a rapid onset of unconsciousness and amnesia in patients. IV infusion of a therapeutic dose of propofol induces anaesthesia with minimal excitement within 40–60 seconds of the injection (the time it takes the injected dose in 1 arm to reach the brain). The half-time of blood-brain equilibration, like that of other fast-acting IV anaesthetic drugs, is roughly 1 to 3 minutes, accounting for the rate of anaesthesia induction. The mechanism of action, as with all general anaesthetics, is poorly known. Propofol is believed to cause its sedative and anaesthetic effects by positively modulating the inhibitory activity of the neurotransmitter GABA through the beta subunit GABA $\alpha$  receptors.<sup>1,2</sup>

Propofol pharmacokinetics is well represented by a 3-compartment linear model, with compartments representing plasma, fast-equilibrating tissues, and slowly equilibrating tissues. Following an IV bolus dosage, there is quick equilibration between the plasma and the brain, which explains the rapid onset of anaesthesia. Plasma levels first fall quickly as a result of both distribution and metabolic clearance. After a propofol bolus, distribution contributes to approximately half of the reduction. However, distribution does not remain constant throughout time; rather, it declines as tissues throughout the body equilibrate with plasma and become saturated. The rate at which equilibration occurs varies depending on the pace and length of the infusion. When equilibration occurs, there is no longer any net transport of propofol between tissues and plasma. Whereas about 1% of total plasma propofol is unbound, the free fraction of propofol in the cerebrospinal fluid (CSF) is approximately 31%. After 30 minutes, the blood and brain concentrations reach equilibrium, yielding a

total blood-to-CSF propofol ratio of 0.01 to 0.02. Because of the rapid initial distribution of a single bolus or short infusion, the time to neutralise clinical effects is brief. Because of its high lipid solubility, propofol can be redistributed to and from a slow compartment. This compartment has a high capacity to absorb propofol, resulting in a very large apparent volume of distribution at steady state (3–4 multiples of total body volume), even in non-obese individuals. Nonetheless, even after extended administration, the clinical effects are neutralised rather quickly as compared to other IV hypnotics because drug redistribution from the slow compartment is slower than metabolism and excretion.<sup>2</sup>

In contrast to other hypnotics, propofol has a typically favourable context-sensitive decrement time. Short infusions (< 3 h) have an 80% decrement time of < 50 min, but the decrement for larger infusions (> 12 h) can reach up to 3.5 hours. Propofol clearance in adults ranges from 23 to 50 mL/kg/min (1.6 to 3.4 L/min in individuals weighing 70 kg). It is primarily removed through hepatic conjugation into inactive metabolites that are excreted by the kidney (Fig. 1). A glucuronide conjugate accounts for nearly half the delivered dosage. In healthy humans, the steady-state volume of distribution for propofol (10-day infusion) is approximately 60 L/kg. In a typical adult, immediate post-anaesthesia recovery occurs after approximately 10 minutes of induction; however, recovery may be slightly delayed in cirrhotic patients.<sup>2</sup>

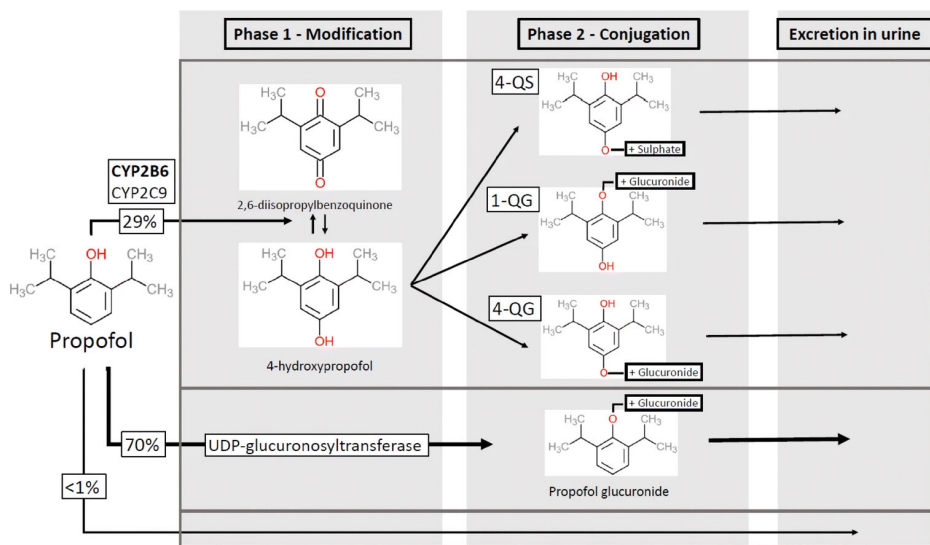


Fig. 1. Propofol metabolic pathway. CYP; cytochrome P450; UDP: uridine 5'-diphosphate; 4-QS: 4-hydroxypropofol sulphate; 1-QG: 1-hydroxypropofol glucuronide; 4-QG: 4-hydroxypropofol-glucuronide. Reproduced from Sahinovic *et al.*<sup>3</sup>

Of all types of liver cancer, HCC is the most prevalent. Overall, primary liver cancer ranks as the fifth most frequently diagnosed cancer and the third most common cause of cancer-related deaths globally.<sup>6</sup> Of the various methods that can be used to treat liver cancer, MCT was chosen for our patient. Skin burns, liver capsule bleeding, and intense discomfort are 3 of the most prevalent MCT consequences. When a tumour is larger than 5 cm in diameter, cancer cells may become thermoresistant and undergo active proliferation, encouraging tumour spread and recurrence. Nonetheless, MCT may outperform conventional therapy options for HCC.<sup>7</sup> Therefore, the procedure shows no correlation with our patient's unfortunate event.

However, as we go back to the disease itself, the activity and protein levels of 7 major cytochrome P450 enzymes have been shown to be significantly and sometimes severely reduced in HCC tumours, most likely due to reduced transcription or mRNA stability. Hence, all the major drug-metabolising CYPs are severely dysregulated by liver cancer carcinogenesis, although the different drugs will be affected differently in different patients.<sup>8</sup> As we discussed earlier, propofol is redistributed from its slow compartment back into circulation after an initial bolus or infusion. If the rate of metabolism of propofol is impaired due to CYP enzyme deficiency, the active metabolite can still exert its full effect even after the patient appears to have recovered from the general anaesthetic effect. Given the absence of other plausible explanations for our patient's postoperative unconsciousness, it is reasonable to conclude that the redistribution of propofol was the cause.

Another likely explanation for our patient's loss of consciousness is propofol infusion syndrome. Propofol infusion syndrome, an uncommon and possibly fatal illness, was initially observed in children in 1990 and more recently in adults undergoing long-term (> 48 h) high-dose propofol infusions (> 5 mg kg<sup>-1</sup> h<sup>-1</sup>). Typical signs of propofol infusion syndrome include lactic acidosis, haemodynamic instability (arrhythmia and hypotension), acute renal injury, rhabdomyolysis, hypertriglyceridemia, and liver failure.<sup>10</sup>

The exact cause of propofol infusion syndrome is not fully understood, but it is believed to be related to mitochondrial dysfunction. Early theories proposed that propofol might act as a mitochondrial uncoupler or interfere with fatty acid oxidation. Studies have shown that propofol may disrupt the respiratory chain, leading to decreased ATP production and metabolic acidosis.<sup>10</sup> It is thought that propofol inhibits enzymes like carnitine palmitoyl transferase I, causing an accumulation of fatty acids in the mitochondria and impairing energy production. Experiments in rats suggest that propofol's structure, similar to that of coenzyme Q, allows it to inhibit electron transfer in the respiratory chain.<sup>9</sup> Microscopic evidence has also indicated mitochondrial damage in cardiac muscle due to propofol. Case

studies have highlighted the importance of the cumulative dose of propofol, with higher rates and longer infusions increasing the risk of the syndrome.<sup>10</sup> However, even low doses can cause issues in individuals with genetic mitochondrial defects.

Mitochondrial dysfunction is a critical contributor to muscle weakness. Mitochondria are the powerhouses of cells, providing the energy necessary for muscle function. When mitochondria are damaged or dysfunctional, they cannot produce sufficient energy, leading to muscle fatigue and weakness, which, in our case, mimicked the “collapse” state of our patient. However, because our patient did not meet *all* the criteria for propofol infusion syndrome, we did not consider it to be the primary cause of our patient’s decrease in GCS.

## Conclusion

Propofol is an IV anaesthetic agent primarily metabolised by the liver through the CYP enzyme system, which also metabolises other drugs. CYP450 deficiency can slow propofol clearance, resulting in higher plasma concentrations of propofol, which in turn can lead to prolonged sedation and respiratory depression. However, it is important to note that CYP450 deficiency is a relatively rare condition and not all patients will exhibit this phenotype. Overall, CYP450 deficiency, such as presumed in our patient, can lead to altered pharmacokinetics of propofol, including impaired metabolism and altered redistribution, which can result in prolonged sedation and anaesthesia. Hence, close monitoring is crucial to ensure patient safety.

## Declarations

### Informed consent for publication

The patient provided informed consent for the publication of the clinical data contained in this case report.

### Competing interests

Dr. Wan Fadzlina Wan Muhd Shukeri serves as Section Editor for Malaysian Journal of Anaesthesiology. She has not been involved in any part of the publication process prior to manuscript acceptance. The remaining authors have no competing interests to declare.

## Funding

None to declare.

## Acknowledgements

None to declare.

## References

1. MIMS Online Team. Fresofol 1% MCT/LCT Full Prescribing Information, Dosage & Side Effects | MIMS Hong Kong. MIMS Hong Kong [Internet]. n.d. Available from: <https://www.mims.com/hongkong/drug/info/fresofol%201percent%20mct-lct?type=full>
2. Suh SJ, Yim HJ, Yoon EL, et al. Is propofol safe when administered to cirrhotic patients during sedative endoscopy? Korean J Intern Med. 2014;29(1):57. <https://doi.org/10.3904/kjim.2014.29.1.57>
3. Sahinovic MM, Struys MM, Absalom AR. Clinical pharmacokinetics and pharmacodynamics of propofol. Clin Pharmacokinet. 2018;57(12):1539-1558. <https://doi.org/10.1007/s40262-018-0672-3>
4. Iwersen-Bergmann S, Rösner P, Kühnau HC, Junge M, Schmoldt A. Death after excessive propofol abuse. Int J Legal Med. 2001;114:248-251. <https://doi.org/10.1007/s004149900129>
5. Propofol - LiverTox - NCBI Bookshelf. Propofol - LiverTox - NCBI Bookshelf. 2020. Available from: <https://www.ncbi.nlm.nih.gov/books/NBK547909/#:~:text=Propofol%20has%20been%20associat-ed%20with,an%20enlarged%20or%20fatty%20liver>
6. Bosetti C, Turati F, La Vecchia C. Hepatocellular carcinoma epidemiology. Best Pract Res Clin Gastroenterol. 2014;28(5):753-70. <https://doi.org/10.1016/j.bpg.2014.08.007>
7. Chen X, Liu HP, Li M, Qiao L. Advances in non-surgical management of primary liver cancer. World J Gastroenterol. 2014;20(44):16630. <https://doi.org/10.3748/wjg.v20.i44.16630>
8. Yan T, Lu L, Xie C, et al. Severely impaired and dysregulated cytochrome P450 expression and activities in hepatocellular carcinoma: implications for personalized treatment in patients severely impaired and dysregulated activities of CYPs in HCC. Mol Cancer Ther. 2015;14(12):2874-2886. <https://doi.org/10.1158/1535-7163.MCT-15-0274>
9. Vanlander AV, Menten B, Smet J, et al. Possible pathogenic mechanism of propofol infusion syndrome involves coenzyme Q. Anesthesiology. 2015;122(2):343-352. <https://doi.org/10.1097/ALN.0000000000000484>
10. Hemphill S, McMenamin L, Bellamy MC, Hopkins PM. Propofol infusion syndrome: a structured literature review and analysis of published case reports. Br J Anaesth. 2019;122(4):448-459. <https://doi.org/10.1016/j.bja.2018.12.025>