

Erector spinae plane block with ropivacaine 0.2% in children: a single-centre case series in a tertiary paediatric centre in Malaysia

Jie Cong **Yeoh**¹, Noor Hasimah Binti **Mohd Sahroni**², Ye Yun **Phang**², Nirawanti **Binti Mohd Said**²

¹Department of Anaesthesiology and Critical Care, Hospital Kuala Lumpur, Wilayah Persekutuan Kuala Lumpur, Malaysia; ²Department of Anaesthesiology and Intensive Care Unit, Hospital Tunku Azizah, Wilayah Persekutuan Kuala Lumpur, Malaysia

Abstract

Erector spinae plane block (ESPB) was first described in 2016 by Forero *et al.* as a modified interfascial plane block used for patients with chronic neuropathic thoracic pain. It was applied in the paediatric population for postoperative pain management as early as 2017. Most evidence on the efficacy of ESPB as postoperative analgesia in the literature is mainly found in case reports, but very few trials had been conducted. This case series describes 4 paediatric patients who received ESPB as part of multimodal analgesia while undergoing different types of surgery, *i.e.*, 1 Kasai procedure, 1 closure of stoma, and 2 thoracotomies. All 4 patients had general anaesthesia for the surgery. No complications were observed in relation to the regional anaesthetic technique. Pain control was achieved with a pain score of 0–2 for 3 patients and 2–4 for 1 patient (thoracotomy) on Day 1 postoperatively, while all of them had a pain score of 0–2 on postoperative Day 2. We found ESPB with ropivacaine 0.2% to be a safe and effective analgesia as part of multimodal

Correspondence: Jie Cong Yeoh, Department of Anaesthesiology and Critical Care, Hospital Kuala Lumpur, Jalan Pahang, 50586, Wilayah Persekutuan Kuala Lumpur, Malaysia
E-mail: yeohjiecong@gmail.com

management of postoperative surgical pain. Further studies are needed to validate this observation.

Keywords: erector spinae plane block, paediatric anaesthesia, pain management, regional anaesthesia, ropivacaine

Introduction

Forero *et al.* first described the erector spinae plane block (ESPB) in 2016.¹ However, the exact mechanism of this technique is still unknown. Ultrasound-guided ESPB is a safe² and effective method as part of multimodal postoperative analgesia.³ To our knowledge, paediatric ESPB has appeared in the literature mainly in case reports and case series, with very few well-designed trials.⁴⁻⁶ To date, there is no standard recommendation on the choice and dosage of local anaesthetic for ESPB in children.⁴⁻⁵ We report a series of cases of variable age ranges with different types of surgeries performed in our centre with ropivacaine 0.2%.

Case presentation

Case 1

A 1.5-month-old baby boy weighing 4.12 kg was admitted with prolonged jaundice and a clinical diagnosis of biliary atresia, presenting signs of obstructive jaundice with abnormal liver function test results and a prolonged activated partial thromboplastin time (APTT). The patient underwent an on-table cholangiogram (OTC) followed by Kasai procedure under general anaesthesia. Due to deranged liver function tests and prolonged APTT, regional analgesia was preferred over central neuraxial blockade during surgery. Maintenance of anaesthesia consisted of sevoflurane/oxygen/air mix along with intravenous (IV) morphine 0.15 mg/kg intraoperatively. ESPB with ultrasound guidance and aseptic technique via Stimuplex A 22-G needle (B Braun Medical S.A, Uriburu, Argentina) was administered with 4 ml ropivacaine 0.2% in total (maximum total dose of 5 ml, 2.5 mg/kg) at T6 level on each side of the ESP with 2 ml each, in lateral position (Fig. 1, labelled as Case 1), as the incision was a rooftop incision. The procedure was performed post-surgery under general anaesthesia prior to extubation without any immediate complications. Morphine infusion at a rate of 15 mcg/kg/hr with face, leg, activity, cry, consolability (FLACC) score = 2 was initiated in the first 12 hours postoperatively and was reduced to 10 mcg/kg/hr by Day 1 and 2 after surgery was completed. This dosage was ceased once feeding became feasible on postoperative Day 3.

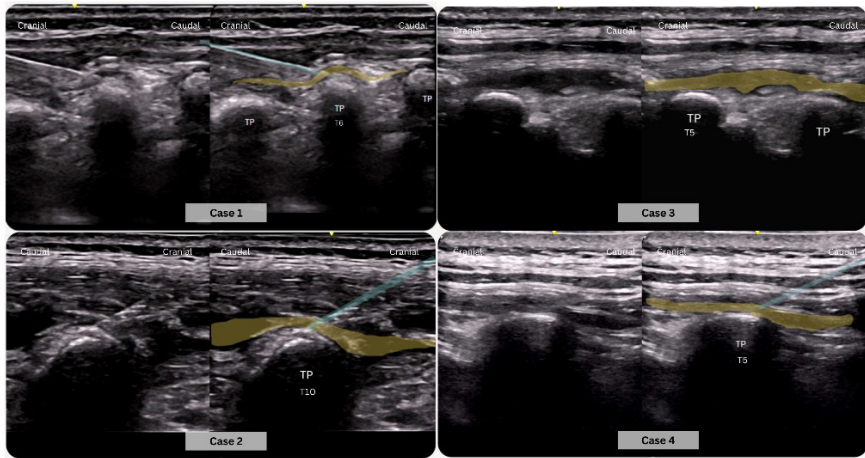


Fig. 1. The spread of local anaesthetic at the erector spinae plane. Yellow: local anaesthetic; blue: needle trajectory, TP: transverse process.

Case 2

An 8-year-old female with a weight of 18.4 kg was electively admitted for stoma closure due to post-perineal canal repair on colostomy. The patient had previously undergone sigmoid colostomy and lay open surgery 3 months prior and was undergoing treatment for relapsed pre-B-cell acute lymphoblastic leukaemia complicated by blinatumomab-induced central nervous system complications. Anaesthesia was maintained via mixed sevoflurane/oxygen and air. ESPB was performed with ropivacaine 0.2% 9 ml (maximum total dose of 23 ml, 2.5 mg/kg) with preservative-free clonidine (1.5 mcg/kg), administered via Stimuplex Ultra 360 20-G (B Braun Aesculap Japan Co Ltd, Ogaki, Japan) needle under ultrasound in-plane technique at the level of T10 in lateral position (Fig. 1, labelled as Case 2). The procedure was conducted under general anaesthesia before extubation. The child experienced no immediate complications and was observed in the regular ward after full recovery from general anaesthesia. Intravenous paracetamol 15 mg/kg was prescribed every 6 hours for a day, then switched to oral once the patient could tolerate oral medication. The postoperative pain score ranged from 0 to 1 on Day 1, and the child sat up in bed postoperative Day 2.

Case 3

A 15-year-old girl weighing 46.3 kg was electively admitted for left thoracotomy and lung nodulectomies due to metastasis from osteosarcoma of the left proximal tibia, which had been treated with chemotherapy followed by resection and mega prosthesis reconstruction 3 months prior to this surgery. The surgery was performed under general anaesthesia with inhalational agents (sevoflurane, oxygen/air mix) using a double lumen endobronchial tube, with IV morphine analgesia (0.15 mg/kg) and a supplement with intercostal nerve block administered by the surgeon at its conclusion. Postoperatively, ESPB with ultrasound-guided in-plane technique via Stimuplex A 21-G needle and aseptic condition administered ropivacaine 0.2% 20 ml (maximum total dose of 57 ml, 2.5 mg/kg) at T5 level in lateral position (Fig. 1, labelled as Case 3), corresponding with the surgical incision site. The child was extubated without any complications. Post-surgery, patient-controlled analgesia (PCA) morphine was prescribed with a dosage of 1 mg/kg/day for the first 24 hours (pain score 2–4), followed by a reduced dosage of 0.6 mg/kg/day on Day 2 (pain score 0–2) before being discontinued entirely on Days 2 and 3 (pain score also 0–2). Multimodal analgesia comprising paracetamol, diclofenac, and oxycodone was introduced before the discontinuation of PCA morphine. There were episodes of vomiting postoperatively (Days 1 and 2) that required additional doses of metoclopramide and ondansetron, likely due to opioid use.

Case 4

A 13-year-old girl, weighing 32.1 kg, was admitted for a left thoracotomy for lung nodulectomies to address recurrent lung metastasis from proximal tibia osteosarcoma. One month prior, she had undergone the same procedure on her right side without complications or decreased effort tolerance. General anaesthesia with double-lumen endobronchial tube insertion was used during surgery, along with IV morphine and intercostal nerve block, under direct visualisation by the surgeon. Postoperative pain management included ESPB using ultrasound-guided technique via Stimuplex A 21-G needle with ropivacaine 0.2% 20 ml (maximum total dose of 40 ml, 2.5 mg/kg) administered at T5 level in lateral position (Fig. 1, labelled as Case 4), corresponding to the surgical incision site. The procedure was performed during general anaesthesia before extubation with no observed complications. Post-operation, PCA morphine was prescribed and her usage within 24 hours ranged from 0.5 mg/kg/day (pain score: 0–2) to 0.2 mg/kg/day on Day 2 (pain score: 0–1). The patient achieved the ability to sit up by Day 2 and was PCA-free on Day 3 with multimodal analgesia including paracetamol, diclofenac, and morphine administered as necessary.

Table 1. Summary of case series described

Variables	Case 1	Case 2	Case 3	Case 4
Age/ Body weight	1.5 months/ 4.12 kg	8 years/ 18.4 kg	15 years/ 46.3 kg	13 years/ 32.1 kg
Type of surgery	Kasai procedure for biliary atresia	Closure of stoma	Thoracotomy for lung nodulectomies	Thoracotomy for lung nodulectomies
Surgical incision	Rooftop incision	Left flank (at the level of umbilicus)	Left thoracotomy (~level T5)	Left thoracotomy (~level T5)
Level of injection	T6	T10	T5	T5
Preop or postop block*	Postop	Postop	Postop	Postop
Choice and volume of local anaesthetic	4 ml ropivacaine 0.2% (2 ml on each side of ESPB) (maximum dose: 5 ml, 2.5 mg/kg)	9 ml ropivacaine 0.2% + 1.5 mcg/kg clonidine as additive (maximum dose: 23 ml, 2.5 mg/kg)	20 ml ropivacaine 0.2% (maximum dose: 57 ml, 2.5 mg/kg) Intercostal nerve block (direct visualization) by surgeon prior to closure	20 ml ropivacaine 0.2% (maximum dose: 40 ml, 2.5 mg/kg) Intercostal nerve block (direct visualization) by surgeon prior to closure
Postoperative choice of analgesia and PS	Morphine infusion: 15 mcg/kg/hr during the 1st 12 hr; reduced to 10 mcg/kg/hr subsequently Opioid free POD 3	Intravenous paracetamol 15 mg/kg for 1 day and switched to oral paracetamol once tolerated orally	PCAM: 1 mg/kg/day for 1st 24 hr (PS 2-4) 0.6 mg/kg/day (PS 0-2) weaned POD 2-3 Oral paracetamol + diclofenac + oxycodone initiated prior to PCAM discontinuation	PCAM: 0.5 mg/kg/day for 1st 12 hr (PS 0-2) 0.2 mg/kg/day (PS 0-2) weaned POD 3 Oral paracetamol + diclofenac + oxycodone initiated prior to PCAM discontinuation
Complication(s)	Nil	Nil	Nil	Nil

*Preop refers to block prior to surgical incision; postop refers to block prior to extubation.
PCAM: Patient-controlled analgesia morphine; POD: Postoperative day; PS: Pain score

Discussion

Paediatric postoperative pain management poses a challenge, especially in infants and young children due to the subjective and complex nature of pain. Distinguishing between various emotional responses, such as anxiety or distress, can be tricky in some cases. Multimodal analgesia has emerged as an alternative approach to reduce opioid consumption during perioperative pain treatment. Regional anaesthesia using ultrasound-guided nerve blocks has gained popularity since its development in the 1990s for use alongside general anaesthesia as multimodal analgesic therapy during surgery.

In 2016, Forero *et al.* introduced the erector spinae plane nerve block,¹ which has since become a reliable and safe technique of multimodal postoperative analgesia. Nevertheless, evidence in relation to paediatric patients remains limited and primarily reliant on case reports.⁴⁻⁶ In this case series, we present 4 cases (Table 1) wherein the application of an ESPB was utilised during intra-abdominal and thoracic surgery procedures performed on paediatric patients.

In the first case, ESPB was preferred over an epidural block due to the patient's coagulopathy.⁷ This technique is deemed safe because it involves administering injections at a site distant from vascular and nerve structures. ESPB served as postoperative analgesia alongside IV morphine administration. The FLACC score was utilised to gauge the pain levels in this patient. A score of 0 for 3 days after surgery is an indication of good pain management. This case study supports the use of ESPB as effective multimodal analgesic combined with a reduced need for IV opioids.

The second case involved the utilisation of ESPB as a form of multimodal analgesia in conjunction with IV paracetamol after surgery. Pain evaluation was conducted by means of the Malaysian Ministry of Health face scale,⁸ revealing that the patient experienced minimal discomfort rated between 0 and 1 from the postoperative period up to 2 days following the procedure, allowing for prompt mobilisation (sitting). ESPB was implemented as supplementary support for postoperative pain management without resorting to opioid administration, supporting its potential use as an alternative method for avoiding opioids and diminishing their undesirable effects. Consequently, this approach can be classified under opioid-sparing surgery techniques.

The third and fourth case studies focused on the use of ESPB during thoracic surgery in the adolescent age group. Administering a thoracic epidural to adolescents in lateral position after general anaesthesia is challenging due to the thoracic spine curvature becoming more prominent in adolescents, which further narrows the space for Tuohy needle introduction, unlike in younger children where

the thoracic vertebrae spines remain almost horizontal.⁹ However, utilising ESPB can effectively decrease postoperative pain when combined with IV opioids and other multimodal analgesia methods for thoracic surgeries. These cases showed reduced opioid consumption per day, which ranged between 0.5 and 1.0 mg/kg/day, along with lower immediate postoperative to postoperative Day 2 pain scores in the range of 0–2.

Positioning

ESPB is often performed in the preoperative stage for adult patients, usually when they are seated and cooperative. However, in paediatric cases, this procedure can only be conducted after the child has been anaesthetised, similar to other regional anaesthesia techniques. As a result, we have the option to administer this block with the patient positioned either prone or lateral; we tend to use the lateral position at our centre. These positions pose some challenges in obtaining a clear view during block application but can be overcome with practice.

Equipment (transducer and needle choice)

The selection of ultrasound probe and needle size relies on the patient's body structure, which varies from newborns to young adults. For neonates, we prefer to use a hockey stick transducer, a high-frequency probe with a smaller footprint for ultrasound-guided regional anaesthetic administration, as it provides more space for needle entry and allows better control of probe angulation. Additionally, there are several options in needle choices between young adolescents and neonates; typically, we use a 25–50 mm Stimuplex echogenic needle (*i.e.*, Stimuplex Ultra 360 20-G needle) for these procedures as it offers improved visualisation of the needle tip during in-plane ultrasound visualisation.

Conclusion

ESPB with ropivacaine 0.2% is safe and effective analgesia as part of multimodal management of postoperative surgical pain in children. Further research is required to better elucidate best practices for paediatric ESPB.

Declarations

Informed consent for publication

The patients and/or their guardian have provided informed consent for the publication of the clinical data contained in this case series.

Competing interests

None to declare.

Funding

None to declare.

Acknowledgements

We would like to thank the Director General of Health Malaysia for his permission to publish this article.

References

1. Forero M, Adhikary SD, Lopez H, Tsui C, Chin KJ. The erector spinae plane block: a novel analgesic technique in thoracic neuropathic pain. *Reg Anesth Pain Med*. 2016;41:621-627. <https://doi.org/10.1097/AAP.0000000000000451>
2. Ecoffey C, Lacroix F, Giaufré E, Orliaguet G, Courrèges P; Association des Anesthésistes Réanimateurs Pédiatriques d'Expression Française (ADARPEF). Epidemiology and morbidity of regional anesthesia in children: a follow-up one-year prospective survey of the French-Language Society of Paediatric Anaesthesiologists (ADARPEF). *Paediatr Anaesth*. 2010 Dec;20(12):1061-9. <https://doi.org/10.1111/j.1460-9592.2010.03448.x>
3. Aksu C, Gurkan Y. Defining the Indications and Levels of Erector Spinae Plane Block in Pediatric Patients: A Retrospective Study of Our Current Experience. *Cureus*. 2018;11(8):e5348. <https://doi.org/10.7759/cureus.5348>
4. Elkoundi A, Bentalha A, Kettani SEE, Mosadik A, Koraichi AE. Erector spinae plane block for pediatric hip surgery - a case report. *Korean J Anesthesiol*. 2019 Feb;72(1):68-71. <https://doi.org/10.4097/kja.d.18.00149>
5. Lucente M, Ragonesi G, Sanguigni Met al. Erector Spinae Plane Block in Children: a Narrative Review. *Korean J Anesthesiol*. 2022 Jul 5. <https://doi.org/10.4097/kja.22279>
6. Aksu C, Şen MC, Akay MA, Baydemir C, Gürkan Y. Erector Spinae Plane Block vs Quadratus Lumborum Block for pediatric lower abdominal surgery: A double blinded, prospective, and randomized trial. *J Clin Anesth*. 2019 Nov;57:24-28. <https://doi.org/10.1016/j.jclinane.2019.03.006>

7. Ayub A, Talawar P, Kumar R, Bhoi D, Singh AY. Erector Spinae Block a safe, simple and effective analgesic technique for major hepatobiliary surgery with thrombocytopenia. *Egyptian Journal of Anaesthesia*. 2018 Oct;34(4):169–72.
8. Ministry of Health Malaysia. Pain as the 5th Vital Sign Guideline: 3rd Edition [Internet]. 2018. Available from: https://www.moh.gov.my/moh/resources/Penerbitan/Program%20Bebas%20Kesakit/Garis%20Panduan/2_in_1_P5VS_Guideline_3rd_Edition_Corrected_2020.pdf
9. Epidural Anaesthesia in Children [Internet]. WFSA Resource Library. [cited 2024 Mar 16]. Available from: <https://resources.wfsahq.org/atotw/epidural-anaesthesia-in-children>